



Minerva Access is the Institutional Repository of The University of Melbourne

Author/s:

Pedersen, M;Omidvarnia, A;Curwood, EK;Walz, JM;Rayner, G;Jackson, GD

Title:

The dynamics of functional connectivity in neocortical focal epilepsy

Date:

2017-01-01

Citation:

Pedersen, M., Omidvarnia, A., Curwood, E. K., Walz, J. M., Rayner, G. & Jackson, G. D. (2017). The dynamics of functional connectivity in neocortical focal epilepsy. *Neuroimage Clinical*, 15, pp.209-214. <https://doi.org/10.1016/j.nicl.2017.04.005>.

Persistent Link:

<https://hdl.handle.net/11343/256133>

License:

[CC BY-NC-ND](#)



# The dynamics of functional connectivity in neocortical focal epilepsy



Mangor Pedersen<sup>a,\*</sup>, Amir Omidvarnia<sup>a</sup>, Evan K. Curwood<sup>a</sup>, Jennifer M. Walz<sup>a</sup>,  
Genevieve Rayner<sup>a,b</sup>, Graeme D. Jackson<sup>a,c</sup>

<sup>a</sup> The Florey Institute of Neuroscience and Mental Health and The University of Melbourne, Victoria, Australia

<sup>b</sup> Melbourne School of Psychological Sciences, The University of Melbourne, Victoria, Australia

<sup>c</sup> Department of Neurology, Austin Health, Heidelberg, Victoria, Australia

## ARTICLE INFO

### Keywords:

fMRI  
Focal epilepsy  
Dynamic connectivity  
Instantaneous phase synchrony  
DRePS  
Connectomics

## ABSTRACT

Focal epilepsy is characterised by paroxysmal events, reflecting changes in underlying local brain networks. To capture brain network activity at the maximal temporal resolution of the acquired functional magnetic resonance imaging (fMRI) data, we have previously developed a novel analysis framework called Dynamic Regional Phase Synchrony (DRePS). DRePS measures instantaneous mean phase coherence within neighbourhoods of brain voxels. We use it here to examine how the dynamics of the functional connections of regional brain networks are altered in neocortical focal epilepsy. Using task-free fMRI data from 21 subjects with focal epilepsy and 21 healthy controls, we calculated the power spectral density of DRePS, which is a measure of signal variability in local connectivity estimates. Whole-brain averaged power spectral density of DRePS, or signal variability of local connectivity, was significantly higher in epilepsy subjects compared to healthy controls. Maximal increase in DRePS spectral power was seen in bilateral inferior frontal cortices, ipsilateral mid-cingulate gyrus, superior temporal gyrus, caudate head, and contralateral cerebellum. Our results provide further evidence of common brain abnormalities across people with focal epilepsy. We postulate that dynamic changes in specific cortical brain areas may help maintain brain function in the presence of pathological epileptiform network activity in neocortical focal epilepsy.

## 1. Introduction

Focal epilepsy is a disease whereby brain networks function abnormally via a variety of underlying genetic and acquired causes (Berg et al., 2010). This makes a precise definition of ‘epilepsy-specific’ brain networks key for understanding neural mechanisms underlying focal epilepsy (Richardson, 2012; van Diessen et al., 2014). Although functional Magnetic Resonance Imaging (fMRI) provides high spatial information about large-scale functional brain networks, standard fMRI connectivity studies only incorporate static features of the data that are present over multiple minutes and therefore fail to account for the paroxysmal hypersynchrony of brain networks that is a cardinal feature of focal epilepsy (Centeno and Carmichael, 2014). A reason why few studies have explored dynamic fMRI connectivity in focal epilepsy is due to fMRI's limited capability to capture hemodynamic response changes of connectivity between and within different brain areas. A ‘sliding-window’ approach is commonly applied to fMRI time series to elucidate dynamic aspects of functional brain connectivity. This method is, however, suboptimal in that reliable characteristics of brain function can only be achieved with relatively long time-windows that can span

the order of minutes, not seconds (Tagliazucchi and Laufs, 2015).

To combine the high spatial resolution that fMRI offers with single fMRI image temporal resolution, we developed Dynamic Regional Phase Synchrony (DRePS - Omidvarnia et al., 2016). DRePS is a dynamic alternative to Regional Homogeneity (a commonly used static measure of local brain connectivity - Zang et al., 2004) that measures instantaneous phase synchrony at each time-point within spatially proximate fMRI voxels (Omidvarnia et al., 2016 - see also Gleason et al., 2012; Pedersen et al., 2017; Ponce-Alvarez et al., 2015, for similar approaches). DRePS is a promising analysis framework for delineating dynamic brain changes in focal epilepsy because of its capability to estimate fMRI dynamic connectivity at the maximal temporal resolution of a repetition time (*TR*; single image volume). In our previous report of healthy people, we demonstrated that DRePS is likely to reflect activity of local network properties responsible for large-scale and synchronous brain network activity (Omidvarnia et al., 2016).

Several lines of evidence suggest that focal epilepsy is characterised by common functional brain abnormalities despite the heterogeneous nature of this patient group. This was first demonstrated by Laufs et al.

\* Corresponding author at: The Florey Institute of Neuroscience and Mental Health, Melbourne Brain Centre, 245 Burgundy Street, Heidelberg, Victoria 3084, Australia.  
E-mail address: [m.pedersen@brain.org.au](mailto:m.pedersen@brain.org.au) (M. Pedersen).

(2011) who used simultaneous electroencephalogram and fMRI (EEG-fMRI) to demonstrate that across temporal and non-temporal focal epilepsy patients with variable foci, ipsilateral piriform cortex was activated during inter-ictal epileptiform discharges (see also Fahoum et al., 2012; Flanagan et al., 2014; Pedersen et al., 2016). Another simultaneous EEG-fMRI study demonstrated that several other brain regions are also commonly activated or deactivated during heterogeneous inter-ictal epileptiform discharges in frontal lobe epilepsy (Fahoum et al., 2012), namely the ipsilateral fronto-insular cortex, mid-cingulate cortex, precuneus, and cerebellum. All of these studies, however, treat the brain as a *static* entity. To enhance our understanding of focal epilepsy as a paroxysmal brain network disease, a cohort of epilepsy patients with heterogeneous foci localisation was selected to examine commonly observed functional network changes in these patients. By calculating the power spectral density of DRePS ( $PSD_{DRePS}$  - i.e., signal variability of local connectivity) we hypothesise that the aforementioned brain regions are also dynamically altered in neocortical focal epilepsy.

## 2. Methods

### 2.1. Subjects and ethics

Included in this study were 21 participants with neocortical focal epilepsy (mean age  $29.0 \pm 11.5$ , 9 female), and 21 healthy controls (mean age  $30.3 \pm 10.2$ , 10 female). No statistical difference of age and gender was seen between the groups. We have previously published data from 15 of these patients in unrelated analyses of fMRI graph theory (Pedersen et al., 2015b) and multivariate pattern analysis (Pedersen et al., 2016). Here, an additional six patients with focal epilepsy were included. The diagnosis of focal epilepsy was based on converging evidence from clinical symptoms, MRI, EEG video monitoring, neuropsychology, and nuclear imaging. Approximately half of the patients (10/21) had frontal lobe epilepsy, although exact foci were heterogeneous. The remaining patients had seizures originating from peri-central cortex ( $n = 5$ ), parietal lobes ( $n = 4$ ), and temporo-occipital-parietal junction ( $n = 2$ ). No patients had mesial temporal lobe seizures or any secondary lesion. In total, 10 individuals (48%) had a right-sided seizure onset, and 10 individuals (48%) had a lesion visible on MRI consistent with subtle focal cortical dysplasia; 6/21 patients underwent surgery for focal cortical dysplasia (all seizure-free insofar), and all fMRI scans used in this study was acquired pre-operatively. Full clinical overview of all patients is provided in Supplementary Table 1. The Austin Health Human Research Ethics Committee approved the study and all participants gave written informed consent.

### 2.2. fMRI parameters and pre-processing

10 min of task-free fMRI were acquired at 3 T (Siemens Skyra, Erlangen, Germany). No EEG was simultaneously recorded during fMRI scans. fMRI data were obtained with a  $TR$  of 3000 ms, echo time of 30 ms and isotropic voxel size of  $3 \times 3 \times 3$  mm. Pre-processing was performed using scripts from SPM12 (Friston et al., 2011) and DPABI (Yan et al., 2016) in a MATLAB R2016a (MathWorks Inc., Natick, Massachusetts, United States) environment. The data were slice-time corrected, realigned (24 motion parameters - Friston et al., 1996), co-registered to the subject's own structural T1-weighted images, and segmented into three separate tissue types (grey matter, white matter, and cerebrospinal fluid). This was done using a diffeomorphic registration algorithm (DARTEL) that creates an average structural brain template from all subject's T1 images (Ashburner, 2007). fMRI images were then normalised into Montreal Neurological Institute space ( $3 \times 3 \times 3$  mm voxel size). The data were band-pass filtered between the narrowband range of 0.03 and 0.07 Hz. This frequency was chosen over more conventional frequency intervals (e.g., 0.01–0.1 Hz) as it theoretically satisfies mathematical requirements for fMRI phase syn-

chrony analysis and also, is minimally affected by respiration and pulse artefacts (Glerean et al., 2012). Average cerebrospinal fluid and white matter signals were regressed out from the data. Image points with high amplitude head-movement (i.e., framewise displacement above 0.5 mm - Power et al., 2012) were interpolated using a cubic spline algorithm. This procedure avoid discontinuous time signals in fMRI data (Thompson and Fransson, 2015). No statistically significant differences in head movement were observed between the two groups.

### 2.3. Dynamic functional connectivity analysis: power spectral density of DRePS

DRePS time series were obtained by estimating TR-resolution regional similarity between fMRI signals within a moving cube of adjacent voxels ( $0.729 \text{ cm}^3$  with our  $3 \times 3 \times 3$  mm voxel size). It generated a 4D map of dynamic local connectivity with the same size of the input fMRI data. The DRePS time series at a typical voxel represents time-varying phase coherence relationships between a central voxel and its immediate 26 neighbouring voxels over the course of the scan. We developed this measure as a dynamic extension of Regional Homogeneity (Zang et al., 2004), which has previously been used for static connectivity analysis of epilepsies (Pedersen et al., 2015a, 2016; Weaver et al., 2013; Zeng et al., 2013; Zhong et al., 2011). Amplitude of DRePS ranges between 0 and 1 covering low to high dynamic local connectivity.

To characterise the dynamic strength of functional connectivity across different brain areas, we calculated average spectral density of the DRePS time series ( $PSD_{DRePS}$ ) at each voxel for each participant. In our previous report, we showed that  $PSD_{DRePS}$  across healthy controls was highest in commonly reported brain network 'hubs' including frontal and parietal association cortex (including the default mode network), and primary visual cortex (Omidvarnia et al., 2016). This suggests that  $PSD_{DRePS}$  contains meaningful information extracted from phase synchrony of local network properties.

Before computing  $PSD_{DRePS}$ , we estimated whether DRePS is a non-stationary process with varying statistical characteristics over time. We used an Augmented Dickey–Fuller test to verify that DRePS time-series are likely to be non-stationary (see Supplementary Fig. 1 – right bar). We also detrended DRePS signals before analysis. This procedure removes the mean (or trend) of a time-series and allows us to predominantly focus on its fluctuation pattern (Mäkinen et al., 2005).

Due to the similar temporal resolution of DRePS and its underlying fMRI data,  $PSD_{DRePS}$  was averaged over its entire frequency spectrum (0 to  $1 / (2TR) = 0.167$  Hz). This value is mathematically equivalent with the total signal energy of DRePS, and is therefore a potential way of summarising the variability of dynamic connectivity data. In Supplementary Fig. 2 we demonstrate high correlational relationship between variance of DRePS and  $PSD_{DRePS}$  (Pearson's  $r^2 = 0.78$ ).

Voxel-wise spatial maps of  $PSD_{DRePS}$  for all focal epilepsy patients with right hemisphere epilepsy (10/21), and an equal number of healthy controls, were 'flipped' to the left hemisphere. This was done to conduct an ipsilateral versus contralateral analysis. The final  $PSD_{DRePS}$  spatial maps were smoothed with an 8 mm full-width-at-half-maximum Gaussian kernel in order to increase the signal-to-noise ratio.

### 2.4. Statistical analysis

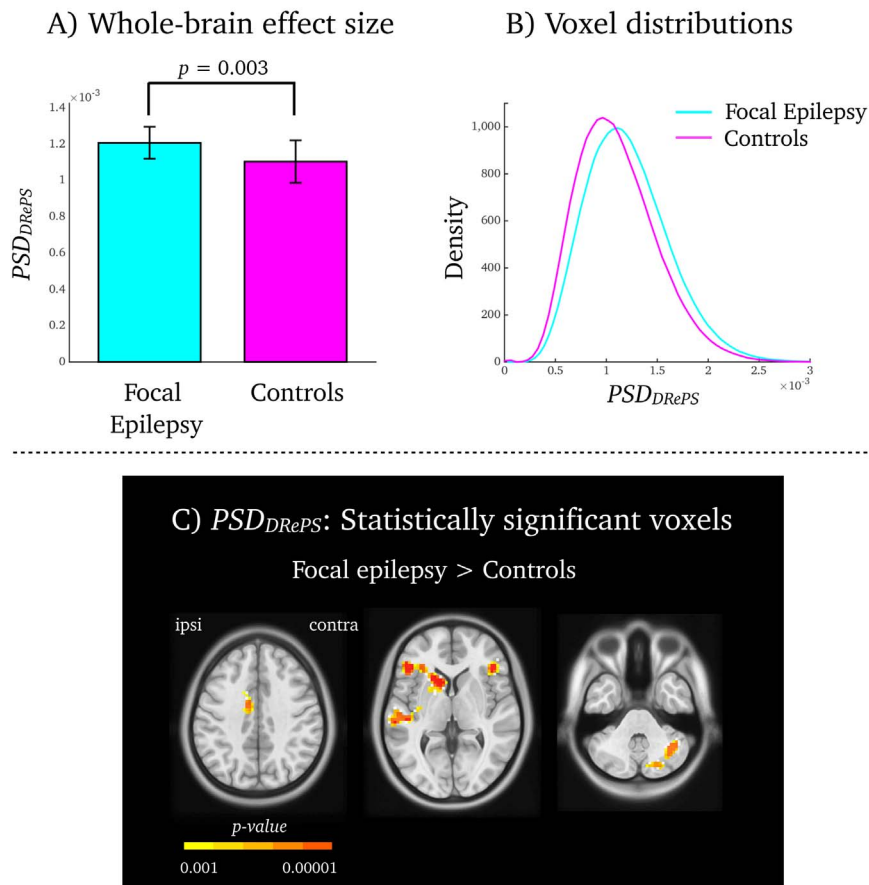
#### 2.4.1. Whole-brain effect sizes

Effect sizes (Cohen's  $d$ ) and 95<sup>th</sup> percentile confidence intervals of whole-brain averaged  $PSD_{DRePS}$  were calculated to estimate overall differences between groups (small effect size = 0.2, medium effect size = 0.5, and large effect size = 0.8).

#### 2.4.2. Voxel-wise effect sizes

A recent appraisal of voxel-wise statistical approaches in fMRI

## Power Spectral Density of DRePS ( $PSD_{DRePS}$ )



**Fig. 1.** Comparison of dynamic functional connectivity between focal epilepsy patients and healthy controls. A) Whole brain effect size analysis between focal epilepsy (cyan) and control (magenta) groups. Error bars denote standard deviation. B) Density of  $PSD_{DRePS}$  voxel-wise distribution for all epilepsy subjects (cyan) and control subjects (magenta). Both groups displayed a heavy-tailed distribution of  $PSD_{DRePS}$  values (reported in hertz across the x-axis). C) Voxel-wise comparison of  $PSD_{DRePS}$  values between focal epilepsy and control groups. Shown are voxel clusters with statistically significant increased  $PSD_{DRePS}$  in focal epilepsy compared to controls. The colour bar corresponds to  $p$ -values associated with voxel-wise permutation testing.

shows that non-parametric statistical analysis of permutation testing is a robust estimator of group differences using fMRI (Eklund et al., 2016). Thus, voxel-wise differences between groups was calculated with non-parametric permutation testing using standardised effect size estimations of Cohen's  $d$ . The voxel-wise data was tested against a null distribution made by 500,000 permutations. For each permutation, subjects were assigned with a random label (i.e., either 'epilepsy' or 'control') and the group difference of Cohen's  $d$  was recalculated. The voxel-wise statistical significance threshold was set at  $p < 0.001$ . Voxels surviving this significance threshold were further cluster-corrected at  $p < 0.05$ .

### 3. Results

#### 3.1. Whole-brain dynamic functional connectivity: focal epilepsy versus controls

Whole-brain averaged  $PSD_{DRePS}$  was increased in epilepsy subjects compared to healthy controls (Fig. 1A; Cohen's  $d = 1.18$ , 95<sup>th</sup> confidence interval = 0.43–1.93,  $p = 0.003$ ; large effect size). In both groups, voxel-wise  $PSD_{DRePS}$  values were associated with heavy-tailed distributions (closest fit was a gamma distribution), but epilepsy subjects had larger number of high  $PSD_{DRePS}$  values (Fig. 1B). In other words, people with neocortical focal epilepsy have stronger fluctuations of local connectivity than healthy controls.

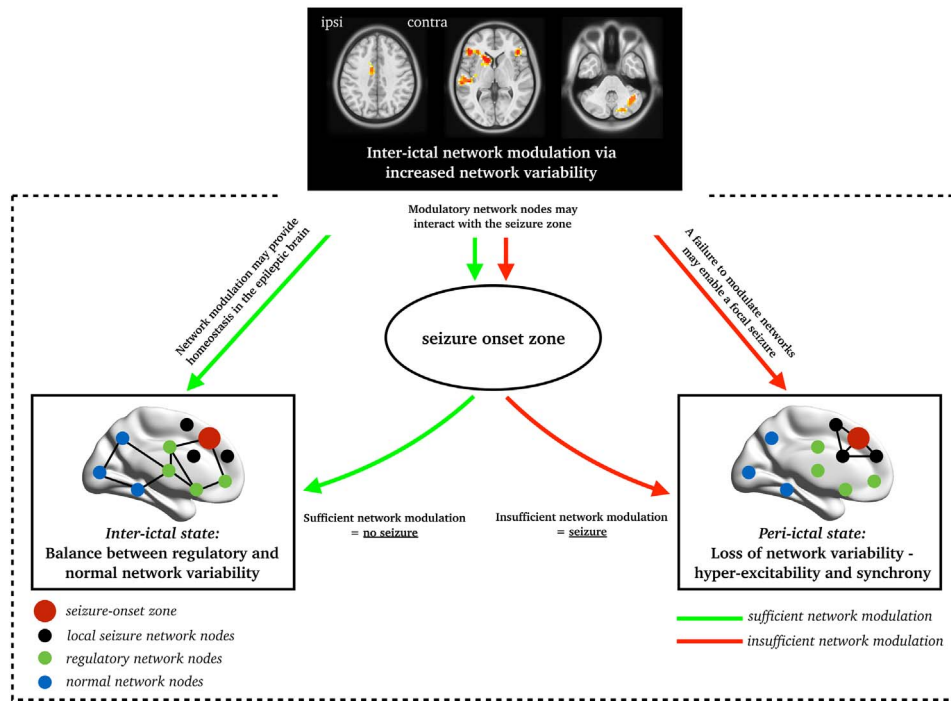
#### 3.2. Voxel-wise dynamic functional connectivity: focal epilepsy versus controls

In focal epilepsy, we detected six brain regions with statistically increased  $PSD_{DRePS}$  as compared to healthy controls. These were bilateral inferior frontal cortices, ipsilateral mid-cingulate gyrus, superior temporal gyrus, caudate head, and contralateral cerebellum ( $p < 0.001$ , cluster corrected – Fig. 1C). No voxels with decreased  $PSD_{DRePS}$  was found in the focal epilepsy group.

#### 3.3. Sub-group analysis: no difference between frontal lobe and non-frontal lobe epilepsy

Since approximately half of our epilepsy patients had some form of frontal lobe epilepsy, we tested whether our findings were 'driven' by this particular sub-group of individuals. We estimated the average  $PSD_{DRePS}$  within each of the six statistically significant spatial clusters (see Fig. 2) and observed no differences between frontal lobe epilepsy patients (Supplementary Fig. 3 – green) and non-frontal lobe epilepsy patients (Supplementary Fig. 3 – blue). Both epilepsy sub-groups showed greater  $PSD_{DRePS}$  than controls (Supplementary Fig. 3 – cyan) for all six voxel clusters.

## Neocortical Focal Epilepsy and Brain Network Variability



**Fig. 2.** Focal epilepsy and brain network variability: Here, we outline a hypothesised model of brain network variability in focal epilepsy during the inter-ictal (bottom left) and peri-ictal (bottom right) state. We propose that the inter-ictal state is associated with ‘regulatory network variability’ that is provided by the inferior frontal cortices, superior temporal gyrus, cingulate cortex and cerebellum. In turn, a functional loss of these modulatory nodes may predispose to focal seizures.

### 3.4. $PSD_{DRePS}$ is distinct from static local connectivity (Regional Homogeneity)

We also examined whether dynamic information obtained from mean  $PSD_{DRePS}$  is correlated with static information of average DRePS and Regional Homogeneity. This was done using data from a randomly selected control subject. As seen in Supplementary Fig. 4, mean DRePS and Regional Homogeneity were highly correlated (Pearson's  $r^2 = 0.89$ ), whereas mean  $PSD_{DRePS}$  and Regional Homogeneity had much weaker correlational relationship (Pearson's  $r^2 = 0.28$ ).

## 4. Discussion

### 4.1. Increased dynamic functional connectivity in neocortical focal epilepsy

This study elucidates the inherent dynamics of functional brain networks in patients with neocortical focal epilepsy, using DRePS to examine dynamic local connectivity at maximal temporal resolution (i.e., single TR) of fMRI data. We observed increased brain-wide  $PSD_{DRePS}$  in people with focal epilepsy compared to controls (Fig. 1A–B). This means that people with neocortical focal epilepsy display stronger fluctuations of local connectivity than healthy controls. This effect was maximal in bilateral inferior frontal cortices, ipsilateral mid-cingulate gyrus, superior temporal gyrus, caudate head, and contralateral cerebellum (Fig. 1C). These are commensurate with our previous findings of static fMRI connectivity abnormalities in focal epilepsy using an unrelated machine learning approach (Pedersen et al., 2016), and also simultaneous EEG-fMRI correlates of inter-ictal epileptiform discharges in frontal lobe and temporal lobe epilepsy (Fahoum et al., 2012). Contrary to previous reports, we observed no between-group differences in either the ipsilateral piriform cortex or the precuneus.

Approximately half of our patients had some form of frontal lobe epilepsy. However, we observed no differences in dynamic local connectivity between frontal lobe epilepsy and non-frontal lobe epi-

lepsy patients. In fact, both sub-groups displayed relatively higher  $PSD_{DRePS}$  than healthy controls (see Supplementary Fig. 3). This suggests that network abnormalities may be consistent across all subjects with focal epilepsy.

To our knowledge, this study is the first to demonstrate abnormalities in fMRI network dynamics in a group of patients with extratemporal focal epilepsy. Several studies have previously shown alterations of fMRI network dynamics in temporal lobe epilepsy (Laufs et al., 2014; Nedic et al., 2015; Robinson et al., 2017). In particular, Morgan et al. (2015) demonstrated that dynamic fMRI connectivity of mid-cingulate and ipsilateral networks (insula, hippocampus and thalamus) was positively correlated with disease duration in temporal lobe epilepsy patients. Taken together, this provides further evidence of ‘common’ brain abnormalities amongst people with clinically heterogeneous focal epilepsy (see Laufs et al., 2011; Fahoum et al., 2012; Flanagan et al., 2014; Pedersen et al., 2016, for further reports of common functional brain abnormalities in temporal and non-temporal lobe focal epilepsy).

### 4.2. Focal epilepsy: increased dynamic functional connectivity may be a compensatory mechanism

Since the current sample of epilepsy patients have seizure foci dispersed across the neocortex, we find it unlikely that the current findings signify network properties that are directly involved in instigation and/or propagation of seizures. Instead we postulate that our findings of increased dynamic brain connectivity in focal epilepsy reflects a brain network process that responds and adapts to epileptic activity characterised by hyper-synchronisation of neurons (Berkovic and Jackson, 2014; Fisher et al., 2005).

The human brain is a highly adaptive and plastic organ that requires homeostatic mechanisms for continued functioning, and is unlikely to be a passive bystander to persistent abnormal neuronal activity. We believe that the epileptic brain engages in a constant ‘battle’ between normal and abnormal brain network activity that is likely to be mediated by *regulatory network activity*. This is consistent with a recent

brain network model proposed by Fornito et al. (2015) where nodes distal to the primary pathology –here, the epileptogenic focus– may increase their overall activity and connectivity in an attempt to regain cortical homeostasis in an otherwise abnormal brain. Such a compensatory mechanism may particularly relate to increased  $PSD_{DRePS}$  seen in the inferior frontal cortices (Fig. 1C). This brain area is known to represent an ‘inhibition hub’ in concert with other nodes including the striatum (Aron et al., 2014). fMRI studies consistently show right inferior frontal cortex activation when participants must selectively suppress a prepotent response during Go-NoGo tasks (Aron and Poldrack, 2006; Hampshire et al., 2010), indicating that this area acts as a ‘brake’ that can suppress or temporarily pause impending motor actions (Aron et al., 2014). Although evidence to date shows a role for this node in behavioural inhibition, we speculate that at a more general level it may also be involved in a compensatory network that attempts to curtail the spread of epileptogenic discharges.

In line with this interpretation, we have previously postulated that brain network segregation (increased connectivity between neighbouring brain nodes) constitutes an inter-ictal network configuration that protects the (focal) epileptic brain from continuously seizing (Pedersen et al., 2015b). Increased network segregation may be mediated by the current ‘focal epilepsy network’ encompassing the fronto-temporal cortex, cingulate gyrus and the cerebellum. In Fig. 2 we provide a schematic overview of how ‘regulatory network variability’ may be important to prevent the epileptic brain from transitioning to the ictal state. Despite the theoretical nature of this model, it is consistent with intracranial EEG studies that demonstrate electrophysiological activity in isolated hubs of a network during focal seizures (Kramer et al., 2010; Le Van Quyen et al., 2003; Ponten et al., 2007; Varotto et al., 2012).

#### 4.3. Dynamic versus static functional connectivity

The assumption of static interdependence between distinct brain areas using task-free fMRI has been dominant in the functional connectivity literature. Despite the valuable contribution of these studies in understanding normal and abnormal brain networks, they always specify an ‘average’ picture of complex brain network dynamics. We believe DRePS is a promising measure of brain dynamics and it is likely to be non-stationary (see Supplementary Fig. 1). This proposition can be further validated using non-parametric and randomised null models (Hindriks et al., 2016). We also show that  $PSD_{DRePS}$  is only moderately correlated with Regional Homogeneity. This finding indicates that dynamic information obtained by  $PSD_{DRePS}$  is distinct from static representations of local brain connectivity (see Supplementary Fig. 3).

By quantifying time-varying or dynamic functional connectivity (e.g.,  $PSD_{DRePS}$ ), we obtain a view of the brain's dynamic interactions (Hutchison et al., 2013). This is especially important when studying brain diseases with paroxysmal characteristics such as focal epilepsy.

#### 4.4. Future directions and limitations

It remains important to test the overall specificity of the brain network changes we have observed in neocortical focal epilepsy. Phenotyping of patient cohorts is generally challenging in epilepsy imaging studies, and although our patients have heterogeneous sites of seizure foci they presumably share a similar disease process in that they all have confirmed or suspected subtle focal cortical dysplasia. An avenue for future research is to test whether other types of epilepsy engage similar networks, including other focal epilepsies (e.g., mesial temporal lobe epilepsy with hippocampal sclerosis, tumours and severe cortical abnormalities), as well as the generalised epilepsies.

Assessing dynamic brain changes in response to epileptogenic EEG discharges would also be a potential improvement of our current approach (e.g., Walz et al., 2017). Commonly used simultaneous EEG-fMRI methods (e.g., general linear model analysis) are not applicable

for  $PSD_{DRePS}$  as it needs information from continuous data. We need novel methods that enable us to extract continuous (epileptogenic) EEG activity that correlates with DRePS.

A limitation of our study is that we were not able to account for functional brain changes potentially caused by anti-epileptic drug use (Jokeit et al., 2001; Pardoe et al., 2013; Yasuda et al., 2013). However, we find it unlikely that our group level results can be accounted for by anti-epileptic drug use given that we found no consistent patterns of anti-epileptic drug use in our patients (e.g., number/type of drugs and years of treatment). In support of this view, we recently demonstrated that functional brain networks change its overall topology between a pre- and post-surgical fMRI scan, despite no changes in antiepileptic drugs (Jackson et al., 2017). This serves as a proof-of-principle that fMRI network findings in epilepsy are likely to reflect disease-specific processes rather than anti-epileptic drugs.

## 5. Conclusion

Increased dynamic network variability may help maintain brain function in the presence of abnormal epileptiform network activity in focal epilepsy – this is also further evidence of common brain network abnormalities amongst people with neocortical focal epilepsy. This study is a step towards understanding focal epilepsy as paroxysmal brain network disease.

Supplementary data to this article can be found online at <http://dx.doi.org/10.1016/j.nicl.2017.04.005>.

## Acknowledgements

We thank Mira Semmelroch, Donna Parker and Magdalena Kowalczyk for assistance with fMRI data acquisition. This study was supported by the National Health and Medical Research Council (NHMRC) of Australia (#628952). The Florey Institute of Neuroscience and Mental Health acknowledges the strong support from the Victorian Government and in particular the funding from the Operational Infrastructure Support Grant. We also acknowledge the facilities, and the scientific and technical assistance of the National Imaging Facility (NIF) at the Florey node and The Victorian Biomedical Imaging Capability (VBIC). GJ is supported by an NHMRC practitioner's fellowship (#1060312). MP was supported by The University of Melbourne scholarships (MIRS & MIFRS).

## References

- Aron, A.R., Poldrack, R.A., 2006. Cortical and subcortical contributions to stop signal response inhibition: role of the subthalamic nucleus. *J. Neurosci.* 26, 2424–2433.
- Aron, A.R., Robbins, T.W., Poldrack, R.A., 2014. Inhibition and the right inferior frontal cortex: one decade on. *Trends Cogn. Sci.* 18, 177–185.
- Ashburner, J., 2007. A fast diffeomorphic image registration algorithm. *NeuroImage* 38, 95–113.
- Berg, A.T., Berkovic, S.F., Brodie, M.J., Buchhalter, J., Cross, J.H., van Emde Boas, W., Engel, J., French, J., Glauser, T.A., Mathern, G.W., Moshé, S.L., Nordli, D., Plouin, P., Scheffer, L.E., 2010. Revised terminology and concepts for organization of seizures and epilepsies: report of the ILAE Commission on Classification and Terminology, 2005–2009. *Epilepsia* 51, 676–685.
- Berkovic, S.F., Jackson, G.D., 2014. “Idiopathic” no more! Abnormal interaction of large-scale brain networks in generalized epilepsy. *Brain* 137, 2400–2402.
- Centeno, M., Carmichael, D.W., 2014. Network connectivity in epilepsy: resting state fMRI and EEG-fMRI contributions. *Front. Neurol.* 5, 93.
- van Diessen, E., Zweiphenning, W.J.E.M., Jansen, F.E., Stam, C.J., Braun, K.P.J., Otte, W.M., 2014. Brain network organization in focal epilepsy: a systematic review and meta-analysis. *PLoS ONE* 9, e114606.
- Eklund, A., Nichols, T.E., Knutsson, H., 2016. Cluster failure: why fMRI inferences for spatial extent have inflated false-positive rates. *Proc. Natl. Acad. Sci.* 113, 7900–7905.
- Fahoum, F., Lopes, R., Pittau, F., Dubeau, F., Gotman, J., 2012. Widespread epileptic networks in focal epilepsies: EEG-fMRI study. *Epilepsia* 53, 1618–1627.
- Fisher, R.S., Boas, W. van E., Blume, W., Elger, C., Genton, P., Lee, P., Engel, J., 2005. Epileptic seizures and epilepsy: definitions proposed by the International League Against Epilepsy (ILAE) and the International Bureau for Epilepsy (IBE). *Epilepsia* 46, 470–472.
- Flanagan, D., Badawy, R.A.B., Jackson, G.D., 2014. EEG-fMRI in focal epilepsy: local

- activation and regional networks. *Clin. Neurophysiol.* 125, 21–31.
- Fornito, A., Zalesky, A., Breakspear, M., 2015. The connectomics of brain disorders. *Nat. Rev. Neurosci.* 16, 159–172.
- Friston, K.J., Williams, S., Howard, R., Frackowiak, R.S., Turner, R., 1996. Movement-related effects in fMRI time-series. *Magn. Reson. Med.* 35, 346–355.
- Friston, K.J., Ashburner, J.T., Kiebel, S.J., Nichols, T.E., Penny, W.D., 2011. *Statistical Parametric Mapping: The Analysis of Functional Brain Images: The Analysis of Functional Brain Images*. Academic Press.
- Glerean, E., Salmi, J., Lahnakoski, J.M., Jääskeläinen, I.P., Sams, M., 2012. Functional magnetic resonance imaging phase synchronization as a measure of dynamic functional connectivity. *Brain Connect.* 2, 91–101.
- Hampshire, A., Chamberlain, S.R., Monti, M.M., Duncan, J., Owen, A.M., 2010. The role of the right inferior frontal gyrus: inhibition and attentional control. *NeuroImage* 50, 1313–1319.
- Hindriks, R., Adhikari, M.H., Murayama, Y., Ganzetti, M., Mantini, D., Logothetis, N.K., Deco, G., 2016. Can sliding-window correlations reveal dynamic functional connectivity in resting-state fMRI? *NeuroImage* 127, 242–256.
- Hutchison, R.M., Womelsdorf, T., Allen, E.A., Bandettini, P.A., Calhoun, V.D., Corbetta, M., Della Penna, S., Duyn, J.H., Glover, G.H., Gonzalez-Castillo, J., Handwerker, D.A., Keilholz, S., Kiviniemi, V., Leopold, D.A., de Pasquale, F., Sporns, O., Walter, M., Chang, C., 2013. Dynamic functional connectivity: promise, issues, and interpretations. *NeuroImage* 80, 360–378.
- Jackson, G.D., Pedersen, M., Harvey, A.S., 2017. How small can the epileptogenic region be?: A case in point. *Neurology*. <http://dx.doi.org/10.1212/WNL.0000000000003962>. E-Pub ahead of print.
- Jokeit, H., Okujava, M., Woermann, F.G., 2001. Memory fMRI lateralizes temporal lobe epilepsy. *Neurology* 57, 1786–1793.
- Kramer, M.A., Eden, U.T., Kolaczyk, E.D., Zepeda, R., Eskandar, E.N., Cash, S.S., 2010. Coalescence and fragmentation of cortical networks during focal seizures. *J. Neurosci.* 30, 10076–10085.
- Laufs, H., Richardson, M.P., Salek-Haddadi, A., Vollmar, C., Duncan, J.S., Gale, K., Lemieux, L., Loscher, W., Koepp, M.J., 2011. Converging PET and fMRI evidence for a common area involved in human focal epilepsies. *Neurology* 77, 904–910.
- Laufs, H., Rodionov, R., Thornton, R., Duncan, J.S., Lemieux, L., Tagliazucchi, E., 2014. Altered fMRI connectivity dynamics in temporal lobe epilepsy might explain seizure semiology. *Front. Neurol.* 5, 175.
- Le Van Quyen, M., Navarro, V., Martinerie, J., Baulac, M., Varela, F.J., 2003. Toward a neurodynamical understanding of ictogenesis. *Epilepsia* 44 (Suppl. 12), 30–43.
- Mäkinen, V.T., May, P.J.C., Tiitinen, H., 2005. The use of stationarity and nonstationarity in the detection and analysis of neural oscillations. *NeuroImage* 28, 389–400.
- Morgan, V.L., Abou-Khalil, B., Rogers, B.P., 2015. Evolution of functional connectivity of brain networks and their dynamic interaction in temporal lobe epilepsy. *Brain Connect.* 5, 35–44.
- Nedic, S., Stufflebeam, S.M., Rondinoni, C., Velasco, T.R., Dos Santos, A.C., Leite, J.P., Gargaro, A.C., Mujica-Parodi, L.R., Ide, J.S., 2015. Using network dynamic fMRI for detection of epileptogenic foci. *BMC Neurol.* 15, 262.
- Omidvarnia, A., Pedersen, M., Walz, J.M., Vaughan, D.N., Abbott, D.F., Jackson, G.D., 2016. Dynamic regional phase synchrony (DRePS): an instantaneous measure of local fMRI connectivity within spatially clustered brain areas. *Hum. Brain Mapp.* 37, 1970–1985.
- Pardoe, H.R., Berg, A.T., Jackson, G.D., 2013. Sodium valproate use is associated with reduced parietal lobe thickness and brain volume. *Neurology* 80, 1895–1900.
- Pedersen, M., Curwood, E.K., Archer, J.S., Abbott, D.F., Jackson, G.D., 2015a. Brain regions with abnormal network properties in severe epilepsy of Lennox-Gastaut phenotype: multivariate analysis of task-free fMRI. *Epilepsia* 56, 1767–1773.
- Pedersen, M., Omidvarnia, A.H., Walz, J.M., Jackson, G.D., 2015b. Increased segregation of brain networks in focal epilepsy: an fMRI graph theory finding. *NeuroImage Clin.* 8, 536–542.
- Pedersen, M., Curwood, E.K., Vaughan, D.N., Omidvarnia, A.H., Jackson, G.D., 2016. Abnormal brain areas common to the focal epilepsies: multivariate pattern analysis of fMRI. *Brain Connect.* 6, 208–215.
- Pedersen, M., Omidvarnia, A., Walz, J.M., Zalesky, A., Jackson, G.D., 2017. Spontaneous brain network activity: analysis of its temporal complexity. *Netw. Neurosci.* [http://dx.doi.org/10.1162/NETN\\_a.00006](http://dx.doi.org/10.1162/NETN_a.00006). E-pub ahead of print.
- Ponce-Alvarez, A., Deco, G., Hagmann, P., Romani, G.L., Mantini, D., Corbetta, M., 2015. Resting-state temporal synchronization networks emerge from connectivity topology and heterogeneity. *PLoS Comput. Biol.* 11, e1004100.
- Ponten, S.C., Bartolomei, F., Stam, C.J., 2007. Small-world networks and epilepsy: graph theoretical analysis of intracerebrally recorded mesial temporal lobe seizures. *Clin. Neurophysiol. Off. J. Int. Fed. Clin. Neurophysiol.* 118, 918–927.
- Power, J.D., Barnes, K.A., Snyder, A.Z., Schlaggar, B.L., Petersen, S.E., 2012. Spurious but systematic correlations in functional connectivity MRI networks arise from subject motion. *NeuroImage* 59, 2142–2154.
- Richardson, M.P., 2012. Large scale brain models of epilepsy: dynamics meets connectomics. *J. Neurol. Neurosurg. Psychiatry* 83, 1238–1248.
- Robinson, L.F., He, X., Barnett, P., Doucet, G.E., Sperling, M.R., Sharan, A., Tracy, J.I., 2017. The temporal instability of resting state network connectivity in intractable epilepsy. *Hum. Brain Mapp.* 38, 528–540.
- Tagliazucchi, E., Laufs, H., 2015. Multimodal imaging of dynamic functional connectivity. *Front. Neurol.* 6, 10.
- Thompson, W.H., Fransson, P., 2015. The frequency dimension of fMRI dynamic connectivity: network connectivity, functional hubs and integration in the resting brain. *NeuroImage* 121, 227–242.
- Varotto, G., Tassi, L., Franceschetti, S., Spreafico, R., Panzica, F., 2012. Epileptogenic networks of type II focal cortical dysplasia: a stereo-EEG study. *NeuroImage* 61, 591–598.
- Walz, J.M., Pedersen, M., Omidvarnia, A., Semmelroch, M., Jackson, G.D., 2017. Spatiotemporal mapping of epileptic spikes using simultaneous EEG-functional MRI. *Brain* 140, 998–1010.
- Weaver, K.E., Chaovalitwongse, W.A., Novotny, E.J., Poliakov, A., Grabowski, T.G., Ojemann, J.G., 2013. Local functional connectivity as a pre-surgical tool for seizure focus identification in non-lesion, focal epilepsy. *Front. Neurol.* 4, 43.
- Yan, C.-G., Wang, X.-D., Zuo, X.-N., Zang, Y.-F., 2016. DPABI: data processing & analysis for (resting-state) brain imaging. *Neuroinformatics* 14, 339–351.
- Yasuda, C.L., Centeno, M., Vollmar, C., Stretton, J., Symms, M., Cendes, F., Mehta, M.A., Thompson, P., Duncan, J.S., Koepp, M.J., 2013. The effect of topiramate on cognitive fMRI. *Epilepsy Res.* 105, 250–255.
- Zang, Y., Jiang, T., Lu, Y., He, Y., Tian, L., 2004. Regional homogeneity approach to fMRI data analysis. *NeuroImage* 22, 394–400.
- Zeng, H., Pizarro, R., Nair, V.A., La, C., Prabhakaran, V., 2013. Alterations in regional homogeneity of resting-state brain activity in mesial temporal lobe epilepsy. *Epilepsia* 54, 658–666.
- Zhong, Y., Lu, G., Zhang, Z., Jiao, Q., Li, K., Liu, Y., 2011. Altered regional synchronization in epileptic patients with generalized tonic-clonic seizures. *Epilepsy Res.* 97, 83–91.